

Monopolar Mania and/or Multiple Sclerosis: A case report*

E. Timuçin ORAL**, Betül YALÇINER***, Figen KARADAĞ**, Hüseyin SARI***, Arif VERİMLİ***

ÖZET

Duygulanım bozukluklarında Manyetik Rezonans Görüntüleme (MRI) çalışmaları ile elde edilen en ilginç bulgular subkortikal beyaz cevherdeki hiperintens görünümüdür. Bu, ventrikül genişlemesi örneğindeki gibi özgül olmayan bir bulgu olmakla birlikte, frontal ve limbik bölgeleri bazal ganglionlara bağlayan yollarda bir bozukluğun varlığı da olasıdır. Bu bulgu ateroskleroz, yaşlanma, iskemi ve demiyelinizan hastalıklarda da görülmektedir. Genç iki uçlu mizaç bozukluğunun birarada görüldüğüne dair de olgu bildirimleri mevcuttur. Birkaç olguda depresyon ya da psikozun nörolojik semptomlardan önce, MS'in ilk belirtisi olarak ortaya çıktığı bildirilmiştir. Burada, 9 yıldan beri yalnızca manik hecmeler ile seyreden ve son hecme sırasında nörolojik belirtilerle ortaya çıkan bir mizaç bozukluğu olgusu sunulmuştur. Nörolojik muayenesinde, artmış derin tendon refleksleri, iki taraflı dorsal taban cildi cevabı, iki taraflı pozitif Hoffman refleksi, disdiadokokinezi, şüpheli sağ hemihipoestezi bulundu. Hastanın düz çizgi üzerinde yürümesi de bozulmuştu. Hastanın MRI'nda ventrikül çevresinde hiperintens beyaz cevher lezyonları saptandı. Beyin omurilik sıvısı bulguları yeterince desteklemediği için de Poser ölçeğine göre "klinik olarak olası MS" tanısı konuldu. Sonuç olarak, bu olgu bize MS gibi iyi bilinen bir nörolojik hastalığın mani gibi bir büyük psikiyatrik bozukluk olarak kendisini ortaya koyabileceğini göstermektedir. Bu, MS'in tüm mizaç bozukluğu olgularında dikkate alınmasının gerekliliğini ortaya koymaktadır.

Anahtar kelimeler: Mizaç bozukluğu, MS, MRI

Düşünen Adam; 1994, 7 (4): 30-33

SUMMARY

The most interesting Magnetic Resonance Imaging (MRI) studies on affective disorders are high incidence of focal sign hyperintensities in subcortical white matter. Although this is a nonspecific finding like ventriculomegaly, there is the probability of damage to pathways connecting limbic and frontal regions with basal ganglia. This can be seen also in atherosclerosis, aging, ischemia and demyelinating disorders. Cause of appearance in young bipolar patients deserves attention. There are also a number of anecdotal reports about the coexistence of bipolar disorders and Multiple Sclerosis (MS). In a few case reports depression or psychosis are presented to be the first manifestation of MS without neurological symptoms. Here 9 years of affective disorder history with only manic episodes that was manifested with neurological symptoms in the latest episode, is presented. Increased deep tendon reflexes, bilateral dorsal planter responses, bilateral positive Hoffmann reflex, dysdiadokokinesia, suspected right hemihypoesthesia were found. Tandem walk was also disturbed. MRI findings of this patient revealed hyperintense white matter lesions in periventricular region. As cerebrospinal fluid findings did not support MS, this case was considered as "clinically probable MS" according to Poser scale. As a result, this case suggests us a well-known major neurological disorder, MS, can manifest itself as a major psychiatric disorder, mania. Therefore, MS should always be considered in all affective disorder patients.

Key words: Mood disorder, MS, MRI

Department of Psychiatry (**), Department of Neurology (***), Bakırköy State Hospital for Psychiatric and Neurological Diseases, İstanbul, TÜRKİYE.

(*) Presented in: "Thrd International Symposium Imaging of the Brain in Psychiatry and Related Fields"

INTRODUCTION

Since the late 1980s, magnetic resonance imaging (MRI) was available in clinical practice and in some studies evidence for neuroanatomical changes in psychiatric disorder, mainly in affective disorders and schizophrenia were reported⁽¹³⁾. Structural abnormalities have been reported in bipolar affective disorder without any known neurological disturbance. The most interesting MRI studies on affective disorders are high incidence of focal sign hyperintensities in subcortical white matter in both bipolar and in elderly depressed patients^(14,17). Dupont et al reported 9 out of 19 MRI scans of this kind of patients revealed hyperintense subcortical abnormalities, without any significance⁽³⁾. Although this is a nonspecific finding like ventriculomegaly, there is the probability of damage to pathways connecting limbic and frontal regions with basal ganglia nuclei. Such lesions are known in other conditions such as atherosclerosis, aging, ischemia and demyelinating disorders. Cause of appearance in young bipolar patients deserves attention because, the finding is not related to patients age, duration of illness, other neurological conditions or treatments. Here, a young mood disorder patient with this kind of MRI findings is presented.

CASE

FG, a 36 year old male patient was, when brought to the emergency unit, aggressive, logorrheic and agitated. He was brought by his family with the help of police who stated that he was spending a lot money, threatening his mother with a knife, shouting at people and being aggressive to his family members. They also stated that he had a periodical problem in his walk for a couple of months. When interviewed he said "I am here to get well to be married as soon as possible". According to his family, he had been getting aggressive for two months, but they said he was not working properly for 15 years. From his various hospital records, it was learned that he had a conversive disorder 16 years ago during his military service in 1978. He was well until he was hospitalized with bipolar affective disorder, manic episode 6 years later in 1984. This was followed by 10 more hospitalizations in the following 3 years with the same diagnosis. He was stable and silent, mostly

drug free as well, for 7 years till his current episode, except a lung tuberculosis history that was manifested a year ago. He had two months of hospital treatment because of tuberculosis other than psychiatric hospitalizations. He had a suspected family history of mood disorder but had no trauma, psychoactive drug abuse or epilepsy history.

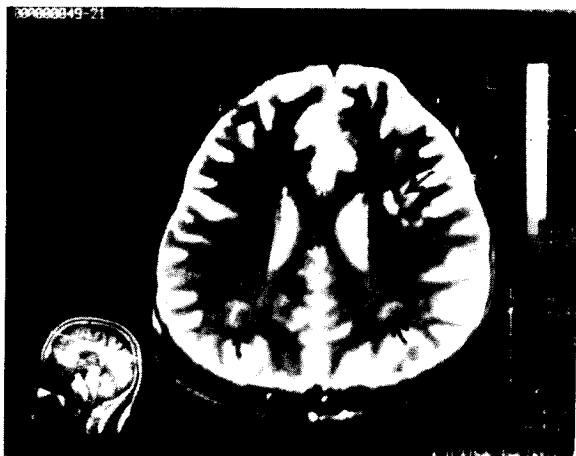
In previous examinations his EEGs were found normal, toxicology screening was negative as were all other medical tests including thyroid hormones. Physical examination revealed a healthy young person until this last episode. In his last neurological examination: increased deep tendon reflexes, bilateral dorsal planter responses, bilateral positive Hoffmann reflex, dysdiadokokinesia, suspected right hemihypoesthesia were found. Tandem walk was also disturbed.

Three common characteristics of those 11 episodes of mania were lithium resistance, neuroleptic drug sensitivity, psychotic features. He only responded partially to haloperidol (average 10 mg/day) in most of his episodes.

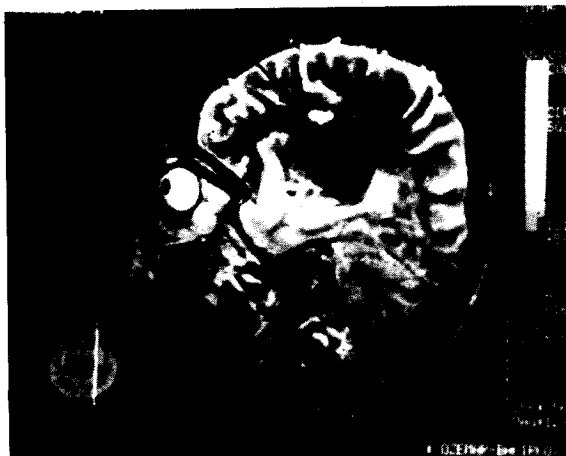Serum immunological findings were as follows in this episode: IgA 144 mg/dl, IgM 208 mg/dl, IgG 802 mg/dl with limits of (90-450), (60-250), (800-1800) sequentially, while they were 162 mg/dl, 280 mg/dl, and 1310 mg/dl a week later. IgG was found 7 mg/dl (0.2-3.8) and 4.6 mg/dl in CSF simultaneously with serum findings. IgG index was found 0.26 that was also in normal limits.

MRI scan was performed with a 0.2 Tesla Unit permanent magnet Hitachi MRT-20 EX; foci of high signal intensity, involving the subcortical white matter, bilateral centrum semiovale, left periventricular region and right anterior capsula interna were detected in PD-T2W (SE, TR:2700 m/sn TE:38, 110 m/sn) axial and (SE, TR: 2000 m/sn TE: 38, 110 m/sn) sagittal images. These foci revealed isointense in T1W (SE, TR: 400 m/sn TE: 20 m/sn) axial and sagittal images (Photographs 1-3).

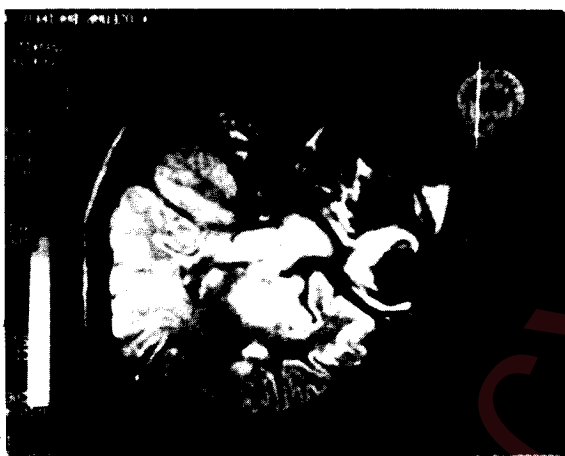As CSF findings did not support MS this case was considered as "Clinically Probable MS" according to Poser scale.



Photograph 1.



Photograph 2.



Photograph 3.

DISCUSSION

There are number of anecdotal reports concerning the coexistence of mania and MS (6,10,15). Cottrell and Wilson in 1926 stated that in MS patients: "... the cardinal symptoms are not neurological, in its limited sense, but belong to emotional, affective and visceral spheres, and are constituted by: 1. Change in mood; 2. Change in bodily feeling; 3. Change in emotional expression and control" (2). Joffe et al. reported that 13 % of MS patients also had bipolar disorder, a rate that is significantly higher than the 1 % expected in the general population (9). This may be an evidence to suggest that this epidemiologically defined association also based on a biological mechanism, such as genetic vulnerability (12). Hutchinson and colleagues hypothesized that bipolar affective disorder may be the initial manifestation of

MS in a group of 7 patients who presented with symptoms of MS but who had a preceding history of bipolar affective disorder, either recurrent manic episodes as in ours or both phases together years before any neurological symptoms. 4 of 7 patients had numerous focal white matter abnormalities in the centrum semiovale and periventricular regions with subcortical white matter lesions (8). Reports of other psychiatric illness occurring before the onset of MS include unipolar depressive illness (1,11) and schizophreniform psychosis (4). In early articles, it was mentioned about a relationship between hysteria and MS. Maybe the true conversion probably more prevalent in patients with MS than in general population but there is still no definitive evidence. In our case, the first evidence of MS either as a psychiatric or a neurological symptom, appeared 6 to 16 years later than conversion symptom which might be better taken as a military service phenomenon rather than MS (7).

Bipolar affective disorder may be an initial symptom of MS, preceding other neurological symptoms by several years and due to the anatomical site of the demyelinating process. On the other hand, there may also be a shared genetical predisposition to both entities in common (8). Ferrier et al. stated that, patchy white matter lesions were found in 7 % of the good outcome patients compared with % 47 of the poor outcome ($p < 0.01$). These results suggest that organic change is found in poor outcome BPD patients and this may explain the anti-kindling effect of anticonvulsants in such cases. However, the outcome in association with lesions in our patient was not so

poor⁽⁵⁾. Case reports by Kellner et al.⁽¹⁰⁾ suggest that lithium carbonate is as effective in controlling mania in patients with MS as it is in patients without MS, this is not the case in our patient. Though he responded in acute phase he did not respond to preventive lithium carbonate especially between 1984-1987, in which he had 3 episodes in a year.

If bipolar disorder may be induced by demyelination, it is probable that the manifestation of mania depends on a complex interaction of a structural lesion with a biochemical process, possibly in relation with a genetic predisposition⁽¹⁶⁾. In our case these MRI findings without any neurological manifestation as in previous episodes of the illness, would have given the idea of idiopathic insignificant subcortical white matter hyperintensities. This result now raises a question of if these patients will manifest some neurological symptoms in their follow up examination or the same MRI lesions in MS and BPD are pointing out the different appearances of the same process.

KAYNAKLAR

1. Berríos GE, Quemada JL: Depressive illness in multiple sclerosis: Clinical and theoretical aspects of the association. *Br J Psychiatry* 156:10-16, 1990.
2. Cottrell SS, Wilson SAK: The affective symptomatology of disseminated sclerosis. *J Neurol Psychopathol* 7:1-30, 1926.
3. Dupont RM, Jernigan TL, Butters N, Delis D, Merselink JR, Heindel N, Gillin JC: Subcortical abnormalities detected in bipolar affective disorder using magnetic resonance imaging. *Arch Gen Psychiatry* 47:55-59, 1990.
4. Feinstein A, Boulay G, Ron MA: Psychotic illness in multiple sclerosis: A clinical and magnetic resonance imaging study. *Br J Psychiatry* 161:680-685, 1992.
5. Ferrier N, Eccleston D, Moore B, Shepherd D, McMillan I: EEG and white matter abnormalities in lithium-resistant bipolar disorder. Present in CIMP Congress, Washington, 1994.
6. Garland EJ, Zis AP: Multiple sclerosis and affective disorder. *Can J Psychiatry* 2:112-117, 1991.
7. Grant I: Neuropsychological and psychiatric disturbances in multiple sclerosis in *Multiple Sclerosis*. Mc Donald WI, Silberberg DH (eds). *Int Med Rev* 1986, p.139-140.
8. Hutchinson M, Stack J, Buckley P: Bipolar affective disorder prior to the onset of multiple sclerosis. *Acta Neurol Scand* 88:388-393, 1993.
9. Joffe RT, Lippert GP, Gray TA, Sawa G, Horvath Z: Mood disorder and multiple sclerosis. *Arch Neurol* 44:376-378, 1987.
10. Kellner CH, Davenport Y, Post RM, Ross RJ: Rapidly cycling bipolar disorder and multiple sclerosis. *Am J Psychiatry* 141:112-113, 1984.
11. Millefiorini E, Padovani A, Pozzili C, et al: Depression in the early phase of MS: influence of functional disability, cognitive impairment and brain abnormalities. *Acta Neurol Scand* 4:354-358, 1992.
12. Minden SL, Schiffer RB: Affective disorders in MS: Review and recommendations for clinical research. *Arch Neurol* 47:98-104, 1990.
13. Pearlson GD, Marsh L: Magnetic resonance imaging in psychiatry in *Review of Psychiatry*. Vol. 12 American Psychiatric Press, Washington DC, 1993, p.347-378.
14. Rabins PV, Pearlson GD, Aylward EH, et al: Cortical magnetic resonance imaging changes in elderly in patients with depression. *Am J Psychiatry* 148:617-620, 1991.
15. Schiffer RB, Wineman NM, Weitkamp LR: Association between bipolar affective disorder and multiple sclerosis. *Am J Psychiatry* 143:94-95, 1986.
16. Schiffer RB, Weitkamp LR, Wineman NM, Guttormsen S: Multiple sclerosis and affective disorder: family history, sex and HLA-DR antigens. *Arch Neurol* 45:1345-1348, 1988.
17. Swayze VW, Andreasen NC, Alliger RJ, et al: Subcortical and temporal changes in affective disorder and schizophrenia: a magnetic resonance imaging study. *Biol Psychiatry* 31:221-240, 1992.