

Corpus Callosum Atrophy and Psychosis: a Case Report

Yasemin Görgülü¹,
Serap Çakıcı Alparlan²,
Niyazi Uygur³

¹Sp. Dr., ²Ass't Dr., ³Clinic Chief Sp. Dr.
Bakırköy Research and Training Hospital for Psychiatry,
Neurology and Neurosurgery 8th Psychiatry Clinic

ÖZET

Korpus kallosum atrofisi ve psikoz: Bir olgu sunumu

Otuz bir yaşındaki erkek hasta, işlediği cinayet suçu nedeniyle ilgili mahkemenin verdiği koruma ve tedavi altına alınması kararı gereğince hastanemize yatırıldı. Hasta, 2001 yılında geçirdiği trafik kazasına bağlı kafa travması nedeniyle yoğun bakım ünitesinde tedavi görmüştü. Hastanın bu kazaya kadar herhangi bir şikayeti ya da hastalığı yokken, kafa travması nedeniyle gördüğü tedavinin tamamlanmasından hemen sonra perseküsyon hezeyanları şeklinde psikotik belirtileri ortaya çıkmıştı. Kendisine düşmanca davrandığı ve kötülük yapacağı şeklindeki perseküsyon hezeyanları nedeniyle halasını öldürmüştü. Hastanın kranial MR'ında, korpus kallosumda total incelme-atrofi saptandı. DSM-IV TR'ye göre hastanın tanısı, "kafa travmasına bağlı psikotik bozukluk, hezeyanlarla giden tip" olarak konuldu. Bu olgu, kafa travması, psikoz ve kafa travmasından sonra saptanan korpus kallosum atrofisi arasındaki zamansal ilişki nedeniyle ilginç bulunmuştur.

Anahtar kelimeler: Korpus kallosum, atrofi, psikoz

ABSTRACT

Corpus callosum atrophy and psychosis: a case report

A 31-year-old male patient was hospitalized in our hospital due to the compulsory treatment decision of the related court because of the guilt of "murder". The patient had been treated in intensive care unit due to head trauma because of a traffic accident, in 2001. The patient had had no complaints or disease until this accident. After his treatment for head trauma, psychotic signs as persecution delusions had appeared. He had killed his aunt because of his persecution delusions as he believed his aunt had been hostile to and would harm him. In his cranial MRI, thinning-atrophy in all parts of corpus callosum was observed. He was diagnosed with "psychotic disorder due to head trauma, with delusions", according to DSM-IV TR. This case is found interesting because of the time relation between head trauma and psychosis and corpus callosum atrophy detected after the head trauma.

Key words: Corpus callosum, atrophy, psychosis

DOI: 10.5350/DAJPN2010230210t

Address reprint requests to:
Uzm. Dr. Yasemin Görgülü, Bakırköy Ruh
Sağlığı ve Sinir Hastalıkları Eğitim ve Araştırma
Hastanesi 8. Psikiyatri Kliniği İstanbul - Türkiye

Phone: +90-212-543-6565/1116

E-mail address:
yasemingorgulu@yahoo.com

Date of acceptance:
June 11, 2010

(This case was presented as a poster presentation on June 02, 2009 at the 7th National Biological Psychiatry Congress.)

INTRODUCTION

The role of structural anomalies in the etiology of schizophrenia and psychotic disorders is important. Various cerebral structures have been held responsible in the etiology in time, as has the corpus callosum (1). The corpus callosum is the junction of the brain between the two hemispheres, connecting the homologous areas of the right and left hemispheres of the cerebral cortex, consisting of around 180 million axons, most of which are myelinated (2). In some schizophrenia patients, a disruption of information flow between the two hemispheres through corpus callosum was reported. Moreover, with data obtained from anatomical studies, a relation was observed between a thickened corpus callosum and both early onset and negative symptoms, and between a thinned

corpus callosum and both late onset and positive symptoms (3).

CASE

A 31-year-old male patient – high school graduate, unemployed and married – was hospitalized in our hospital by decision of the relevant court that he must receive care and treatment after having committed the crime of premeditated murder.

The patient had not had any disease or complaint and worked as an electrician until 2001, when he had a car accident and consequently was treated in the intensive care unit for head trauma. Immediately after completion of the treatment for head trauma, the patient began to show psychotic symptoms in the form of delusions of persecution. The patient

received drug treatment for these psychotic symptoms for approximately three years but then he stopped taking his medication. As the patient's treatment records could not be accessed, no reliable information on his examination findings and treatments could be obtained. He was not able to work after the accident, as his occupational functionality was disrupted. About five years after the accident, he stabbed his aunt to death because of his persecutory delusions that she was doing him wrong and was his enemy. He was subsequently arrested and sent to prison.

In his first psychiatric examination, he was conscious, cooperative and oriented. His speaking speed was slow, his affect was blunt, his mood was irritable, his associations normal and relevant. No delusions or hallucinations were detected. When he talked about the crime he had committed, a disruption in his ability to judge and reality testing was observed. His abstract thought was partially intact and his knowledge was limited. His memory and attention examination results were considered sufficient.

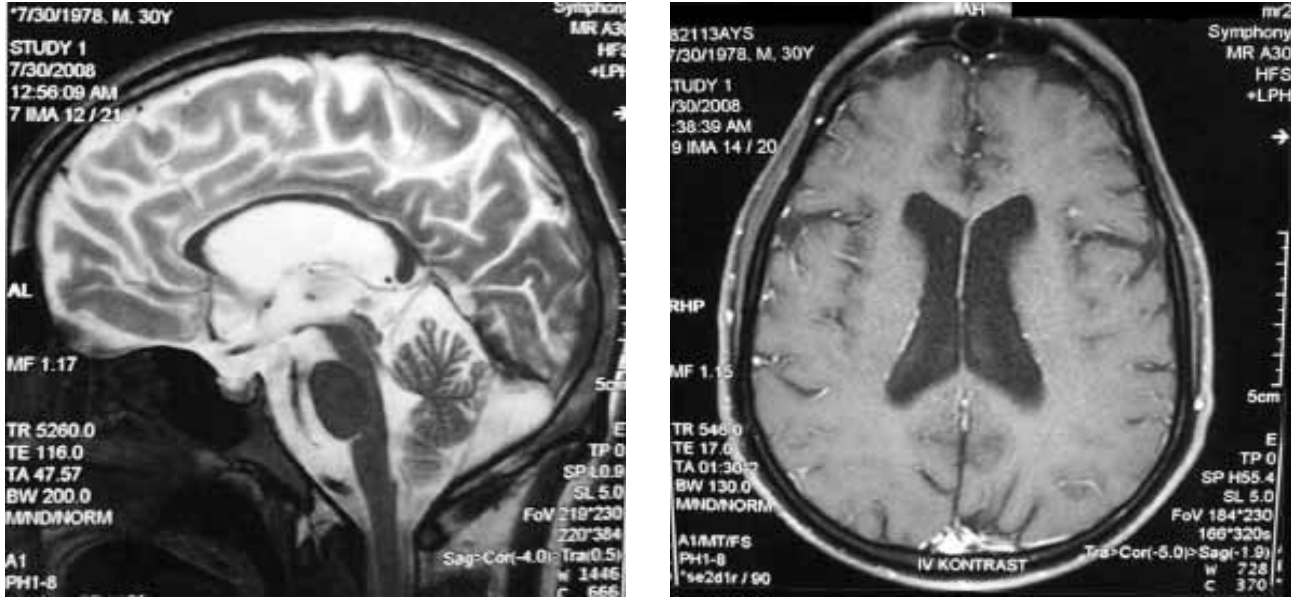
After the patient was admitted to the psychiatry department, he was immediately transferred to the clinic for chest diseases for existing "miliary tuberculosis". During his follow-up care at the clinic for chest diseases, auditory hallucinations and delusions of persecution, as well as disorganized speech and behaviour, were detected. He was started on a treatment of haloperidol 20 mg/day and biperidene 4 mg/day concurrently with his anti-tuberculosis treatment. As the patient exhibited aggressive behaviour because of his auditory hallucinations and persecutory delusions, and was causing difficulties for the staff at the clinic, carbamazepine 400 mg/day was added to his treatment to control his aggressive behavior. The patient, who ceased to be tuberculosis infective some time later, was taken back to the psychiatry department and his treatment was resumed. His symptoms slowly abated; the carbamazepine dose was decreased and then stopped. The patient, whose psychotic symptoms recovered noticeably with a combination treatment of haloperidol 20 mg/day, chlorpromazine 300 mg/day and biperidene 4 mg/day, is still being treated in our department. His tuberculosis treatment was continued,

reduced, and then discontinued by the clinic for chest diseases.

There were no signs other than the car accident in the patient's personal background, and no features in his family history. He used no psychoactive substances other than cigarettes. There were no features in his laboratory tests. His EEG examination was considered normal.

Neuropsychological examination: The patient was subjected to the Edinburgh Handedness Inventory, a number sequence test for attention evaluation, and a verbal memory process test for verbal memory evaluation, Wechsler memory scale visual sub-test for non-verbal memory evaluation, and the cube drawing test to evaluate visuospatial function and construction abilities. Language functions were examined to evaluate the patient's left hemisphere functions and the Wisconsin card-matching test was administered to evaluate executive (frontal) functions. The Stroop test, clock-drawing test, verbal fluency test, and other mental control tests and disconnection tests to evaluate corpus callosum functions were administered. The patient used his right hand for tasks requiring one hand, and both hands were within normal limits. Moderate astereognosis (in 2/10 articles) was detected in the right hand. He was able to write with both his right and left hands. Visuospatial function and construction capacities and mimicking of hand posture in the opposite hand was normal in both hands. No disorder in the ability to locate a certain point in the opposite half of the body was detected. There were no findings of corpus callosum dysfunction as evaluated by neurological tests. Mild verbal and non-verbal memory impairment accompanying attention deficit and concentration deficit, as well as distinct findings concerning the frontal axis, were observed. Relative memory and verbal memory were evaluated as more defective than non-verbal memory. Findings concerning the frontal axis included difficulty in suppressing the tendency to reply improperly, difficulty in switching categories, inadequate mental control, difficulty in planning, and reduced verbal fluency.

In the patient's neurological examination performed as part of the requested neurological consultation,



Şekil 1-2: Kranial MR'da, serebral atrofi, beyaz cevherde özgül olmayan iskemik gliotik değişiklikler ve korpus kallosumda atrofi

a weakness in the lower extremity distals was accompanied by a stocking-glove type sensation disorder, while the bilateral sole skin reflex test was unresponsive. Deep tendon reflexes, however, were seen to be mildly sensitive. The other neurological examination findings were normal.

In the cranial MRI examination, cerebral atrophy (more distinct in the front parietal zone), non-specific gliotic changes in the white matter, and thinning/atrophy in all structures of the corpus callosum were observed (Figures 1 and 2). Changes in the corpus callosum detected via MRI were interpreted as secondary to the trauma. As a result of the examinations and evaluations made, the peripheral neuropathy detected in the patient's neurological examination was evaluated, according to examinations carried out, as a side effect of the anti-tuberculosis drugs.

According to DSM-IV TR diagnosis criteria, the patient's diagnosis meets the diagnosis criteria A, B, C, and D for schizophrenia, but does not meet diagnosis criteria E, on the grounds that the patient had not had any psychiatric disease prior to the head trauma and that psychiatric symptoms began after the head trauma. Given the patient's head trauma and his general medical condition of corpus callosum atrophy, considered to have developed secondarily to this, the patient was

diagnosed as having "psychotic disorder related to head trauma, type continuing with delusions". According to DSM-IV-TR diagnosis criteria, the main feature of a psychotic disorder connected to a general medical condition is the presence of distinct hallucinations and delusions causing the judgment that a general medical condition is directly connected to physiological effects. For the diagnosis, data indicating that the delusions or hallucinations are a direct physiological result of a general medical condition must be obtained from the patient's history, physical examination, and laboratory findings. The presence of a temporal relation (with onset, relapse, or recovery periods) between the general medical condition and the psychosis, and the presence of atypical features not particular to the primary psychotic disorder such as starting age, family history, and in rare cases hallucinations support the diagnosis of psychotic disorder connected to a general medical condition (4).

DISCUSSION

As the patient had not had any health problems prior to the car accident, he did not have any previous brain images. In the neurology consultation, the corpus callosum atrophy seen in the patient was interpreted as

secondary to the trauma. The necessary examinations were carried out to find out whether the patient's clinical presentation and existing MRI findings were connected to tuberculosis or another organic reason and no finding indicating any disease could be detected.

The patient's cranial MRI revealed thinning/atrophy in all structures of corpus callosum, cerebral atrophy (more distinct in the front parietal zone), and non-specific ischemic gliotic changes in the white matter. That the thinning in corpus callosum is distinct suggests that the psychotic symptoms are related to the corpus callosum anomaly, rather than the other changes. Although a distinct disorder was not detected in tests for corpus callosum functions carried out as part of the neuropsychological evaluation of the patient, whose corpus callosum atrophy was distinct in the cranial MRI, a deterioration in frontal executive functions, including in particular difficulty in suppressing improper replies, difficulty switching categories, inadequate mental control, difficulty in planning, and reduced verbal fluency were observed. The fact that the corpus callosum remained intact despite atrophying could explain how its functions remained within normal limits as far as can be evaluated in neuropsychological tests. Corpus callosum atrophy has, however, been seen as responsible for psychotic symptoms in this patient. Previous studies reported that neuropsychological examinations may not reveal a problem despite the presence of corpus callosum atrophy or total agenesis and that no deficit may occur in functions with a partially intact corpus callosum (5,6). In studies by Sauerwein et al., where controls with corpus callosum total agenesis and normal controls were compared, no difference in transmission tasks between hemispheres was observed between the two groups (6). This situation is explained by the increased use of ipsilateral and subcortical pathways (7,8).

Although there are numerous post-mortem studies, case reports, clinical studies, and meta-analyses on

the relation between psychotic disorders and corpus callosum anomalies, different results have been obtained over the years. In a post-mortem study, a one-mm increase was detected in the thickness of the corpus callosum in schizophrenia patients (9). Thereafter, interest in this subject heightened. In a meta-analysis comparing schizophrenia patients and controls, a statistically significant decrease in the corpus callosum area was shown (10). On the other hand, Günther et al. claimed that an increase in the corpus callosum area was related to positive symptoms and a decrease related to negative symptoms (11). Woodroff et al. showed an inverse relationship between corpus callosum size and delusions (10,12). Nasrallah et al. detected no difference in corpus callosum thickness between male schizophrenia patients and controls. They found that corpus callosum thickness increased in female schizophrenia patients (13). In another study, schizophrenia patients did not differ from controls in terms of the complete corpus callosum area (14). However, similar to our case, most authors reported a smaller corpus callosum area in schizophrenia patients (15-18). Keshavan et al. claimed that there may be fewer axonal fibers connecting cortical areas through the corpus callosum in schizophrenia (16). What is more, corpus callosum agenesis was detected in some schizophrenia patients (19-21).

In the neurology assessment of changes detected in the MRI - even though these changes were interpreted as secondary to trauma - the fact that there is no brain imaging of the patient from before the accident limits the usefulness of the imaging.

This case is interesting because of the temporal relation between head trauma, psychosis and the distinct corpus callosum atrophy detected after the head trauma. It was found worthy of presentation because of the corpus callosum atrophy developing after head trauma in a person known to be healthy, and the potential connection to psychotic symptoms.

REFERENCES

1. [David AS. Schizophrenia and the corpus callosum: developmental, structural and functional relationships. Behav Brain Res 1994; 64:203-211.](#)
2. [Josse G, Seghier ML, Kherif F, Price CJ. Explaining function with anatomy: language lateralization and corpus callosum size. J Neurosci 2008; 28:14132-14139.](#)

3. [Coger RW, Serafetinides EA. Schizophrenia, corpus callosum, and interhemispheric communication: a review. *Psychiatry Res* 1990;34:163-184.](#)
4. Amerikan Psikiyatri Birliği Ruhsal Bozuklukların Tanısal ve Sayımsal Elkitabı, Dördüncü Baskı, Yeniden Gözden Geçirilmiş Tam Metin (DSM-IV-TR). Köroğlu E (Çeviri Ed.). Ankara: Hekimler Yayın Birliği, 2007, 473-478.
5. [Marangolo P, De Renzi E, Di Pace E, Ciurli P, Castriota-Skandenberg A. Let not thy left hand know what thy right hand knoweth. The case of a patient with an infarct involving the callosal pathways. *Brain* 1998; 121:1459-1467.](#)
6. [Sauerwein H, Lassonde MC. Intra- and interhemispheric processing of visual information in callosal agenesis. *Neuropsychologia* 1983; 21:167-171.](#)
7. [Sauerwein HC, Lassonde MC, Cardu B, Geoffroy G. Interhemispheric integration of sensory and motor functions in agenesis of the corpus callosum. *Neuropsychologia* 1981;19:445-454.](#)
8. [Forget J, Lippé S, Lassonde M. Perceptual priming does not transfer interhemispherically in the acallosal brain. *Exp Brain Res* 2009; 192:443-454.](#)
9. [Rosenthal R, Bigelow LB. Quantitative brain measurements in chronic schizophrenia. *Br J Psychiatry* 1972; 121:259-264.](#)
10. [Woodruff PW, McManus IC, David AS. Meta-analysis of corpus callosum size in schizophrenia. *J Neurol Neurosurg Psychiatry* 1995; 58:457-461.](#)
11. [Günther W, Petsch R, Steinberg R, Moser E, Streck P, Heller H, Kurtz G, Hippus H. Brain dysfunction during motor activation and corpus callosum alterations in schizophrenia measured by cerebral blood flow and magnetic resonance imaging. *Biol Psychiatry* 1991; 29:535-555.](#)
12. [Woodruff PW, Pearson GD, Geer MJ, Barta PE, Chilcoat HD. A computerized magnetic resonance imaging study of corpus callosum morphology in schizophrenia. *Psychol Med* 1993; 23:45-56.](#)
13. [Nasrallah HA, Andreasen NC, Coffman JA, Olson SC, Dunn VD, Ehrhardt JC, Chapman SM. A controlled magnetic resonance imaging study of corpus callosum thickness in schizophrenia. *Biol Psychiatry* 1986; 21:274-282.](#)
14. [John JP, Shakeel MK, Jain S. Corpus callosal area differences and gender dimorphism in neuroleptic-naive, recent-onset schizophrenia and healthy control subjects. *Schizophr Res* 2008;103:11-21.](#)
15. [Bachmann S, Pantel J, Flender A, Bottmer C, Essig M, Schroder J. Corpus callosum in first-episode patients with schizophrenia-a magnetic resonance imaging study. *Psychol Med* 2003; 33:1019-1027.](#)
16. [Keshavan MS, Diwadkar VA, Harenski K, Rosenberg DR, Sweeney JA, Pettegrew JW. Abnormalities of the corpus callosum in first episode, treatment naive schizophrenia. *J Neurol Neurosurg Psychiatry* 2002; 72:757-760.](#)
17. [Tibbo P, Nopoulos P, Arndt S, Andreasen NC. Corpus callosum shape and size in male patients with schizophrenia. *Biol Psychiatry* 1998; 44:405-412.](#)
18. [Woodruff PW, Phillips ML, Rushe T, Wright IC, Murray RM, David AS. Corpus callosum size and inter-hemispheric function in schizophrenia. *Schizophr Res* 1997; 23:189-196.](#)
19. [Hallak JE, Crippa JA, Pinto JP, Machado de Sousa JP, Trzesniak C, Dursun SM, McGuire P, Deakin JF, Zuardi AW. Total agenesis of the corpus callosum in a patient with childhood-onset schizophrenia. *Arq Neuropsiquiatr* 2007; 65:1216-1219.](#)
20. [Motomura N, Satani S, Inaba M. Monozygotic twin cases of the agenesis of the corpus callosum with schizophrenic disorder. *Psychiatry Clin Neurosci* 2002; 56:199-202.](#)
21. [Kocabıyık A, Alibaşoğlu H, Tomruk N, Alpay N. Korpus kallosum agenezisi ve şizofreni: Bir olgu sunumu. *Düşünen Adam Psikiyatri ve Nörolojik Bilimler Dergisi* 2006; 19:103-109.](#)